



PATIENT

Rosie Sosely

PRESENTING CLINICAL SIGNS

re check prev u/s 11/7 Owner reports doing well no concerns

Abnormal PE/Chem/CBC/UA Results: U/A proteinuria, hematuria PH 9.0 CBC/Chem WNL

SPECIES

Canine

ULTRASONOGRAPHIC EXAMINATION OF THE ABDOMEN

Urinary System

BREED

Lab Mix

The urinary bladder, trigone, cystourethral junction, and visible pelvic urethra to a depth of 3 cm exhibited normal thickness and tone. Anechoic urine was present in the lumen with no evidence of urine/lumen sediment, mineral, or calculi. The ureteral papillae were normal. The ureters were not visible which is normal. No evidence of inflammatory or neoplastic changes was noted.

SEX

FS

Normal size and margination were present in the kidneys. A normal 1:3 cortex / medulla ratio and normal corticomedullary definition were maintained. The echogenicity of the cortex was similar to or slightly less than normal liver parenchyma while the medulla echogenicity was hypoechoic to the cortex with no evidence of pelvic dilation. The left kidney measured 5.8 cm in length. The right kidney measured 5.8 cm in length.

AGE

3

The area of the aortic trifurcation was free of pathology.

The area of the uterine remnant appeared normal and free of pathology.

WEIGHT

90

Adrenal Glands

The left adrenal gland was uniform in size and contour with a uniformly hypoechoic parenchyma. The left adrenal gland measured 0.57 cm width at the caudal pole. The right adrenal gland was uniform in size and contour with a uniformly hypoechoic parenchyma. The right adrenal gland measured 0.58 cm width at the caudal pole.

INTERPRETED BY

R. McKenzie Daniel,
DVM, DABVP
(Canine and Feline)

Spleen

The spleen exhibited a finely textured and homogenous parenchyma which was hyperechoic to the liver and renal cortical parenchyma. The capsule was smooth and regular without apparent expansion. The splenic vasculature at the hilus was normal in volume with no evidence of congestion or thrombosis. Acute to chronic inflammatory, neoplastic, or benign parenchyma changes were not noted.

IMAGING PERFORMED BY

Jenn

Liver/Gallbladder

HOSPITAL NAME

Rockaway Animal
Hospital

The liver was subjectively normal in size, structure, and contour. The liver parenchyma was uniform and hypoechoic to the spleen with a mild coarse echotexture. Normal vascular volume. The hepatic and portal vasculature were normal in appearance without signs of congestion. The gallbladder was non-distended in size with thin walls and primarily anechoic luminal content. The cystic and common bile ducts were normal.

REFERRING VET

Dr Maniar

Gastrointestinal

**INVOICE
23087**

The stomach presented intact wall layering with a normal wall layer ratio. The lumen of the stomach was empty with no signs of ileus, obstruction or foreign material.

**DATE
12/02/2025**

The small intestine presented intact wall layering with 1:3 muscularis/mucosa ratio. The lumen of the small intestine was empty with no signs of mechanical/metabolic ileus, obstruction or foreign material.



PATIENT

Normal visible colon wall layers were present with apparent formed feces in lumen.

Rosie Sosely

Pancreas

The parenchyma of the left limb, body and right limb of the pancreas presented isoechoic to the adjacent omental fat. A normal curvilinear capsule contour of the pancreas was present. The visible pancreatic duct was normal. No signs of active inflammation or neoplastic disease was evident.

SPECIES

Canine

Free Abdomen

BREED

No omental masses, overt lymphadenopathy or peritoneal effusion was present.

Lab Mix

ULTRASONOGRAPHIC FINDINGS

Primary

SEX

- Sonographically normal urinary bladder and visible proximal urethra
- Normal bilateral kidneys

FS

AGE

INTERPRETATION OF THE FINDINGS & FURTHER RECOMMENDATIONS

3

Further renal staging to include urine C/S and protein: creatinine ratio on sterile urine sample may be considered.

WEIGHT

90

INTERPRETED BY

R. McKenzie Daniel,
DVM, DABVP
(Canine and Feline)

IMAGING PERFORMED BY

Jenn

HOSPITAL NAME

Rockaway Animal
Hospital

REFERRING VET

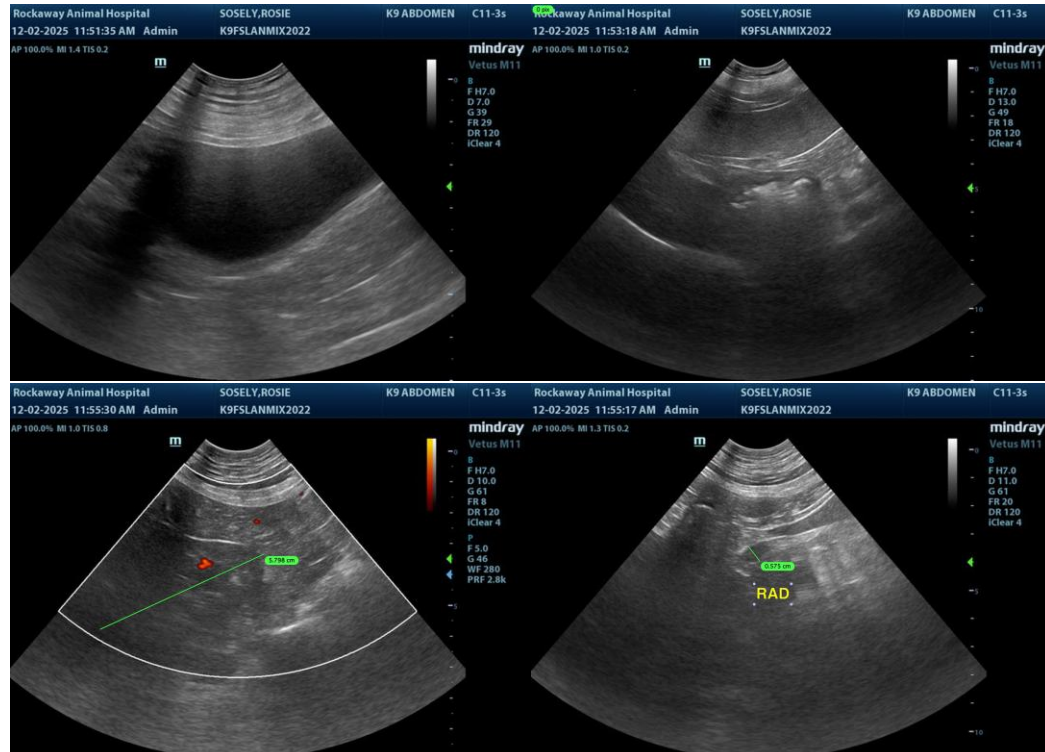
Dr Maniar

INVOICE

23087

DATE

12/02/2025





PATIENT

Rosie Sosely

SPECIES

Canine

BREED

Lab Mix

SEX

FS

AGE

3

WEIGHT

90

INTERPRETED BY

R. McKenzie Daniel,
DVM, DABVP
(Canine and Feline)

IMAGING PERFORMED BY

Jenn

HOSPITAL NAME

Rockaway Animal
Hospital

REFERRING VET

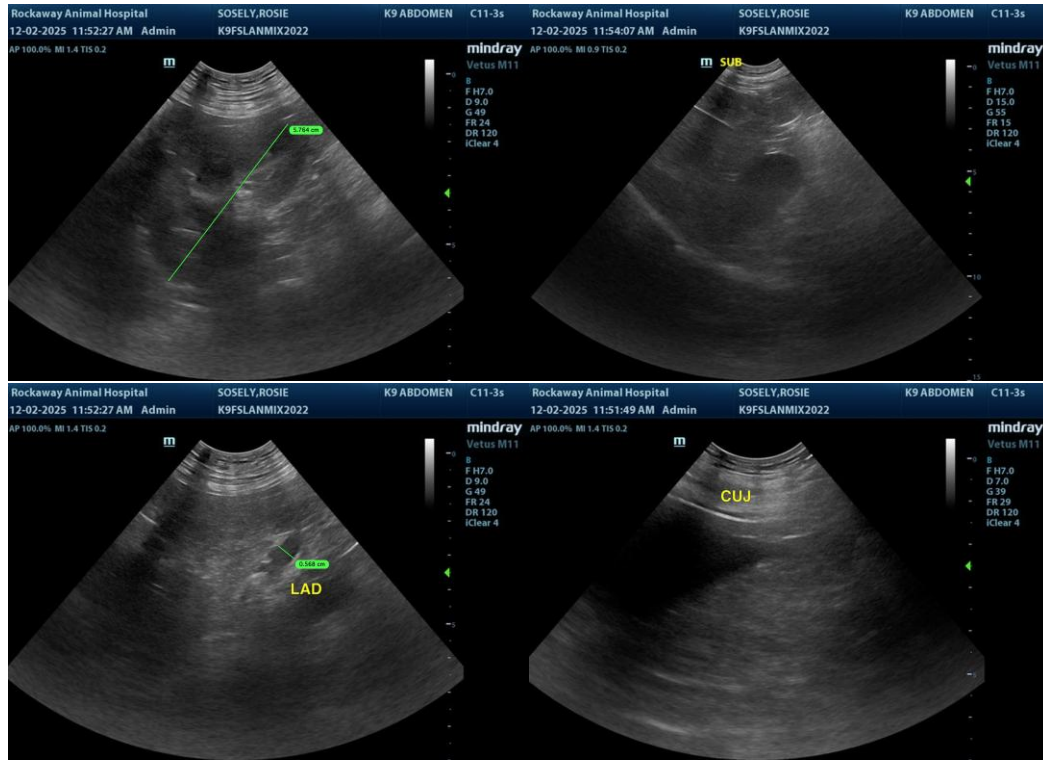
Dr Maniar

INVOICE

23087

DATE

12/02/2025



The information and recommendations provided are based on the images presented by the referring veterinarian/sonographer. No evaluation can be communicated regarding pathology that was not visible in the image/video clips provided.

Thank you for this referral. If the clinical or image interpretation does not parallel your findings or if I can be of any further assistance, please contact me.

R. McKenzie Daniel, DVM, DABVP (Canine/Feline Practice)
info@sonopath.com